



“Video-assisted thoracoscopic surgery for thoracic pleural Lipoma”

Kashyap Nitin

MS, MCh, Assistant Professor, Trauma and emergency, AIIMS, Raipur, CG, India.

Sharma Nitin

MS, M.Ch. Assistant professor, Paediatric surgery, AIIMS, Raipur, CG, India.

Singha Subrat

MD, Additional Professor, Anaesthesia, AIIMS, Raipur.

Minal Wasnik

MD, Assistant Professor, Department of Pathology, RIMS, Raipur.

Patel Vivek

MS, Senior resident, Trauma and emergency, AIIMS, Raipur, CG, India.

ABSTRACT

Thoracic pleural lipoma are extremely rare location lesions in the setting of benign mesenchymal neoplasm of adipose tissue. They are also called as universal tumour as they can be present anywhere in body. Usually asymptomatic in nature but can cause compressive symptoms due to its large size. We are reporting a case of symptomatic thoracic pleural lipoma in which VATS was helpful in successful extirpation.

KEYWORDS

Pleural lipoma, Video assisted Thoracoscopic surgery, Pain, endobronchial tube

Introduction

Lipomas are a very common benign mesenchymal neoplasm but its intra-thoracic location is an extremely rare finding. Video-assisted surgery with its advancements is really helpful in decreasing the morbidity of the patient in such cases.

Case Report

A 53-year male patient was evaluated for right sided mild chest pain in our OPD. Pain was intermittent in nature and was present for last 4 years. His clinical examination was unremarkable. His x-ray chest showed a well circumscribed shadow in the right upper lung field (Figure-1a). Patient was evaluated with contrast enhanced computed tomography (CECT) of chest. Ct Chest reported a well-defined non enhancing non-calcific homogenous lesion 5x5 cm in size extending from the 4th to 6th intercostal space laterally placed with obtuse angle with chest wall in parietal pleura of thoracic cavity (Figure-1b). All routine investigations were within normal limit. Patient was very much anxious about his problem after the discovery of lesion in his chest. It was thus decided to remove the mass due to the associated anxiety and concern of the patient. Because of the location of the lesion and possible excision of the mass thoracoscopically it was decided to do thoracoscopic excision of the mass. Patient was intubated using double lumen endobronchial tube size 37 Fr. This helped us in selective ventilation and to collapse the side to undergo thoracoscopy. Patient was placed in the left lateral position. The primary port (5mm) was placed in the 6th intercostal space at the mid clavicular line under proper control. The thoracic cavity was inspected through the primary port and the lesion was localized. Two other ports (5mm) were placed at the 8th and 7th intercostal spaces at the anterior and the posterior axillary line under vision keeping in mind the triangulation and ergonomics. (Figure- 2) The middle port at the 8th intercostal space was used for vision and the two ports at 6th and 7th intercostal space were used as the working ports. The instruments used were 5mm scissors, graspers, Maryland and suction with monopolar cautery as the energy source. Using the monopolar scissor the capsule was opened and the mass was excised circumferentially using the working ports. The specimen was extracted using the custom made specimen retrieval bag and specimen was removed from the anterior port. (Figure 4) The duration of surgery was 45 minutes and the postoperative period was smooth and uneventful. The intercostal drain was removed at day 4 and patient was discharged at day 6.

Discussion

Thoracic lipoma is a rare and slow growing soft tissue tumour of adipomatous origin. (1) Thoracic lipomas are subcategorized into three type :endobronchial, parenchymal and pleural type. It takes many years to grow into a very large size and cause compressive symptoms. (2)The management protocol for thoracic pleural lipoma is not well defined. Most of time these thoracic lipomas are incidental finding on ski-gram or CT scan while evaluating the patient for another problem. CECT is the most important investigating tool in making the diagnosis of pleural based mass. It is very difficult to differentiate between lipoma and liposarcomatous lesion on the basis of CT scan. (3) Our patient presented with atypical intermittent mild right sided chest pain since last four years. Patient was very much anxious after knowing his finding of delicate location of tumour. Considering wait and watch policy over surgery is a very difficult decision for a surgeon. Many surgeons recommend surgery specially VATS as definite treatment option for thoracic pleural lipomas. (4, 5) We considered VATS in this particular case due to the following advantages:

- Minimal Pain and associated morbidity with VATS
- Better vision and assess to the mass
- Confirming the histo-pathological diagnosis with minimal trauma.
- Reduction in the symptoms

We feel that VATS is an easy and safe procedure for lesions like these for a surgeon who has started his career in minimal invasive surgery. In our case patient had very minimal requirement of analgesic medication during the post-operative period and he was very much satisfied with the results.

Conclusion

Video-assisted thoracoscopic surgery is easy and safe to perform in case of thoracic pleural lipoma. This will help in confirming the diagnosis and decreasing the morbidity.

Figure legend: Figure 1: x ray and CT Showing the mass lesion

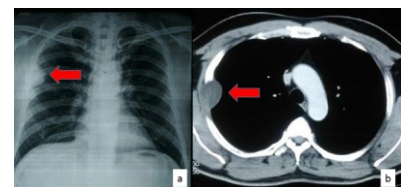
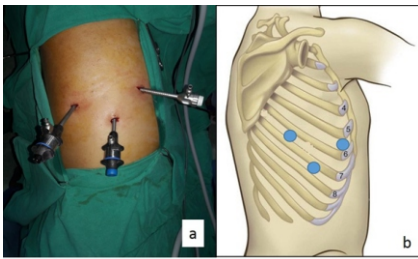
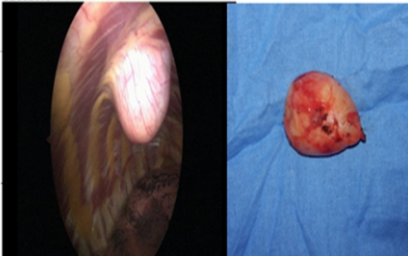


Figure 2: Port position during the procedure**Figure 3: (a) Thoracoscopic view of the lesion. (b) Excised lesion****References**

1. Prasad S, Ramchandra L, Agarwal S, Sharma D. Successful management of pleural lipoma by video-assisted thoracoscopic surgery. *J Minim Access Sur.* 2012;8(1):19-20
2. Alfano DF, Totaro M, Giaganti M. Case report of pleural lipoma: wait and see or surgery? *International journal of medicine and pharmacy.* 2014; 2:37-43
3. Jayle c, chahine JH, Allain G, MiliinS, Soubiron L, Corbi P. Pleural lipoma: a non surgical lesion? *Interactive cardiovascular and thoracic surgery* 2012; 14:735-73
4. Takayama T, Hirai s, ishihara, Kumazaki s Sano K, mishima, etal. Pleural lipoma : Report of a case. *Surg Today*, 1994; 24; 173-175
5. Oka S, Uramoto H, Hanagiri T. Successful extirpation of thoracic pleural lipoma by single-port thoracoscopic surgery. *Asian journal of Surgery.* 2011; 34:140-142